

The Extensor Pollicis And Indicis Communis Muscle

Dr. Tania Marur*, Dr. Mehmet Yıldırım**

* Asisstant Professor in Department of Anatomy, Istanbul University, Cerrahpaşa Medical Faculty, Istanbul-TURKEY

** Professor in Department of Anatomy, Istanbul University, Cerrahpaşa Medical Faculty, Istanbul-TURKEY

ÖZET

MUSCULUS EXTENSOR POLLICIS VE INDICIS COMMUNIS

50 yaşındaki bir erkek kadavranın sağ önkolunun arka yüzünde aksesuar bir kas olan m.extensor pollicis et indicis communis tesbit edildi. Bu varyasyonun görülme sıklığı %1-5 olarak bildirilmektedir. Kas m.extensor pollicis longus ve extensor indicis proprius arasında bulunmaktaydı. Kasın tendonu dorsal dördüncü sinoviyal kompartmandan geçtikten sonra ikiye ayrılıp baş ve işaret parmağının ekstansör yüzünde sonlanmaktaydı. Bu çalışmanın amacı el cerrahisinde önemli olabilecek az görülen bu varyasyonu incelemektir.

Anahtar Sözcükler: Extensor pollicis et indicis communis, fuzyon, gros anatomi, varyasyon.

SUMMARY

In the posterior compartment of the right forearm an additional muscle termed extensor pollicis and indicis communis was observed in a 50-year-old male cadaver. The rare prevalence of this variation is stated to be 1%-5%. The muscle was located between extensor pollicis longus and extensor indicis proprius. After passing through the dorsal fourth synovial compartment its tendon split into two slips to be inserted into the extensor hood of both the thumb and index finger. The aim of this study is to describe this rare variation which may be important during operative procedures on the hand.

Key Words: Extensor pollicis and indicis communis, fusion, gross anatomy, variation.

INTRODUCTION

Extensor pollicis and indicis communis is a supernumerary extensor muscle between the extensor indicis proprius and extensor pollicis longus in presence of both with a doubled tendon and insertion into the thumb and index finger (1-5). The term extensor pollicis and indicis communis was introduced by Wood in 1867 (1). In 1871 Macalister described this muscle originating from the ulna, interosseous membrane and intermuscular septum between the extensor indicis proprius and extensor pollicis longus (2). Its tendon divides into two slips, attaches to the thumb and index finger. A report (3) of this muscle occurring in the absence both of extensor indicis proprius and extensor pollicis longus was also made.

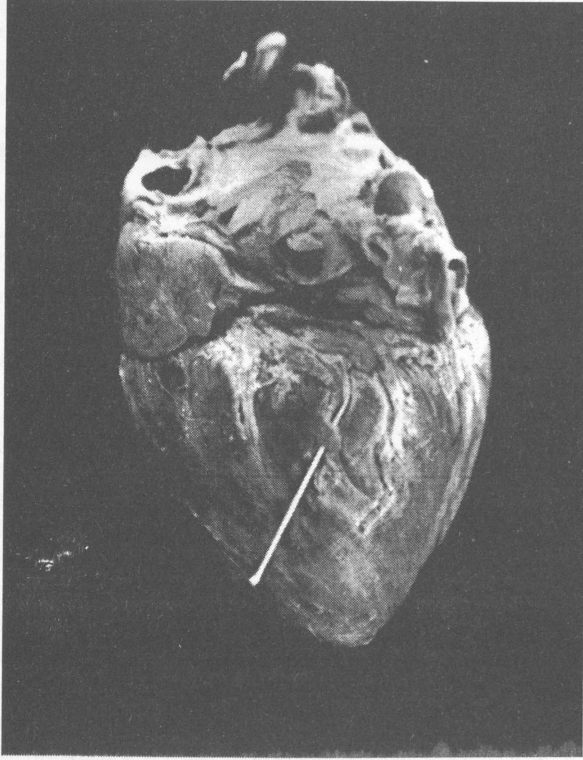
MATERIAL AND METHODS

A supernumerary extensor muscle with a doubled tendon was observed during an anatomical dissection of an 50-year-old male cadaver in the department of anatomy of Cerrahpaşa Medical Faculty. The muscle belly was fused with that of extensor indicis proprius.

For better observation we divided the extensor retinaculum between the dorsal 3rd and 4th synovial compartment and retracted the extensor digitorum communis medially.

FINDINGS

The variation occurred unilaterally in the dorsal compartment of the right forearm. The unipennate muscle arose from the middle third of the posterior surface of the ulna and adjacent interosseous membrane in the plane between the extensor indicis proprius and extensor pollicis longus. Covered with a common fascia, the muscle belly was fused with that of the bipennate extensor indicis proprius muscle (Figs. 1,2 and 3). The muscle belly measured 0.3 cm. in thickness, 5 cm. in length. The muscle converged into a slender 10 cm. long tendon which passed through the dorsal fourth synovial compartment containing the tendons of the extensor indicis proprius laterally and extensor digitorum communis superficially (Fig.1). Between the bases of the I. and II. metacarpal bones its tendon divided into two slips to be finally inserted into the base of the

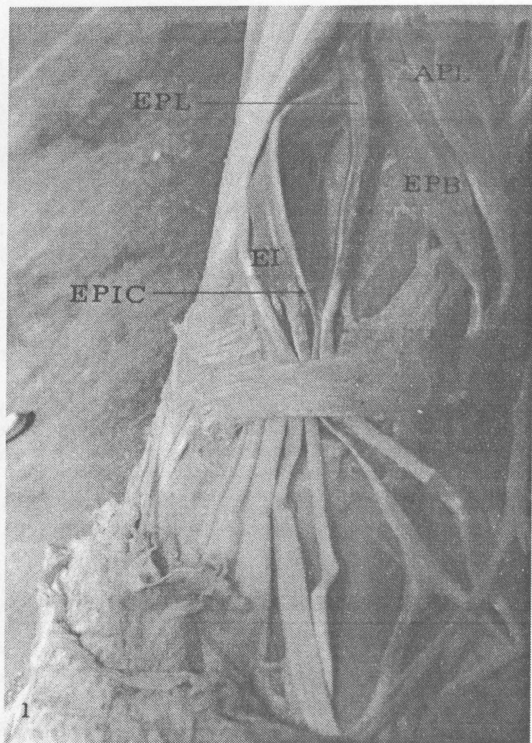


Resim 3. Köpek kalbinde R. circumflexus'un dalı üzerindeki MCB.

KAYNAKLAR

1. Angelini P, Trievellato M, Donis J, Leacchman RD: Myocardial Bridges: A review, Progres in cardiovascular Diseases, 26(1): 75-88, 1983.
2. Anncı K, Şakul BU, Karahan ST: Myocardial köprüler, Optimal Tıp dergisi: 2(39): 126-128, 1989.
3. Dursun N, Ştı RN, Tıpırdamaz S, Erden H, Çelik İ: Evcül memeli hayvanlarda köprüleri üzerinde makroskopik ve mikroskopik arařtırmalar. S.Ü.Vet.Fak. Derg., 8.2:12-17, 1992.
4. Mouraditis B, Lomas FE, McGill D: Thallium-201 myocardial SPECT in myocardial bridging. The Journal of Nuclear Medicine, 36(6): 1031-1033, 1995.
5. Van Nie CJ, Vincent JG: Myocardial bridges in animals. Anat. Histol. Embryol, 18:45-51, 1989.
6. Hadziselimovic H, secerov D, Gmaz-Nikulın E: Comparative anatomical investigation on coronary arteries in wild and domestic animals. Acta. Anat. 90:16-35, 1974.
7. Barilla F, Romeo F, Rosano GMC, Valente A, Reale A: Co-

- ronary artery loops and myocardial ischemia. American Heart Journal, 122(1): 225-226, 1991.
8. Bashour TT, Mansour N, Lee D: Multiple cüronary arterial loops as a cause of myocardial ischemia. American Hert Journal, 126(1): 219-221, 1993.
9. Ferreira AG, Trotter SE, Konig B, Decourt LV, Fox K, Olsen EG: Myocardial bridges morphological and functional aspects. Br. Heart. J. 66(5): 364-7, 1991.
10. Juilliere Y, Berder V, Stuy-Selton C, Buffet P, Danchin N, Cherrier F: İsolated myocardial bridges with angiographic milking of the anterior descending artery: a long term follow-up study. Am.Heart.J. 129(4): 663-5, 1995.
11. Kramer JR, Kitazume H, Proudft WL, Sones FM: Clinical significance of isolated coronary bridges: Benign and frequent condition involving the left anterior descending artery. American Heart Journal, 103(2): 283-288, 1982.
12. Tali T, Mansour NN, Lee D: Multiple coronary arterial loops as a cause of myocardial ischemia. American Heart Journal, 126(1): 219-221, 1993.
13. Karahan ST, Sürücü HS, Karaöz E: chronic degenerative changes in the myocardium supplied by bridged coronary arteries in eight postmortem samples. Jpn Circ J, 62:691-694 1998.
14. Bezerra AJC, Prates JC, Didio LJA: İncidence and clinical significance of bridges of myocardium ove the coronary arteries and their branches. Surg. Radiol. Anat. 9:273-280, 1987.
15. Ishii T, Hosoda Y: The significance of myocardial bridge upon Atherosclerosis in the left anterior descending artery. Journal of Pathology, 148: 279-291, 1986.
16. Sahni D, Jit I: İncidence myocardial bridges in Northwest İndians. İndian-Heart J. 43(6):431-6, 1991.
17. Teofilovski G, Filipovic B, Bogdanovic D, rankovic A, Stankovic G, DiDio LJA: Myocardial bridges over coronary arteries in cercopithecus. Ann. Anat. 174: 435-439, 1992.
18. Ge J, Erbel R, Rupprecht HJ, Koch L, Kearney PH, Gorge G, Haude M, Meyer J: Comparison of intravascular ultrasounda nd angiography in the assessment of myocardial bridging. Circulation. 89: 1725-1732, 1994.
19. Teofilovski G, Parapid G, Nikolic V, rankovic A, Blagotic M, Kreclovic G: Coronary arteries in the Macac monkey. Srp. Arh-Celok-Lek. 121(8-12): 117-9, 1993.
20. Teofilovski G, Parapid G, Nikolic V, Oklobzija M, Rankovic A, Mrvaljevic D: Myocardial bridging of the left anterior descending artery in Macaca hearts. Folia-Morphol-Warsz, 53(1):27-32, 1994.
21. Yıldız A, Özdemir F, Karaca I, Çolak R, Arslan İN: Miyokardial bantların klinik önemi ve körener kan akımına olan etkisi (bir olgu nedeniyle) Ç.Ü. Tıp Fak. Derg. 22:57-60 1997.
22. Polacek P: Relation of myocardial bridges and loops on the coronary arteries to coronary occlusion. Am. Heart J. 61: 44-52 1961.



Figür 1. Tendon of the extensor pollicis and indicis communis passing deep to the extensor retinaculum.

EPL: Extensor pollicis longus.

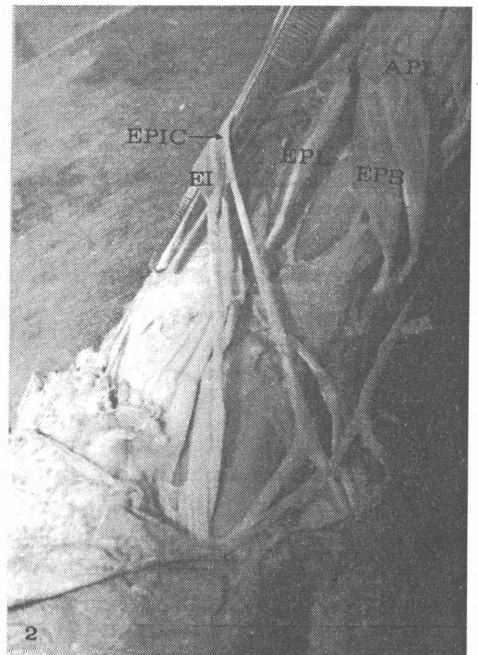
EI: Extensor indicis proprius

EPIC: Tendon of the extensor pollicis and indicis communis.

proximal phalanx of the thumb and extensor expansion of the index finger . On the dorsal aspect of the thumb the one additional slip 3 cm. long was located medial to the tendon of the extensor pollicis longus . The other one 4.5 cm. long extended lateral to the tendons of the extensor indicis proprius and extensor digitorum communis for the index finger on its dorsal aspect (Fig. 2). This muscle was found to be innervated by the deep branches of the radial nerve.

DISCUSSION

The extensor pollicis and indicis communis is one of the rare muscle variations, and is found in 1 to 5 percent of human forearms (1,3,4,6). It is commonly present in dogs (2), cats and rabbits (7), and beavers (1). This muscle named by Wood, originates from the ulna between the extensor pollicis longus and extensor indicis proprius with which it coexists (1). Its tendon divides into two slips, one to the thumb and the other to the index finger (1-5, 8). This variation may also occur in absence of the extensor pollicis longus and extensor indicis proprius (3). Doubling of the extensor pollicis longus and extensor indicis proprius, and their tendons



Figür 2. Dorsal aspect of the right forearm and hand with the divided extensor retinaculum

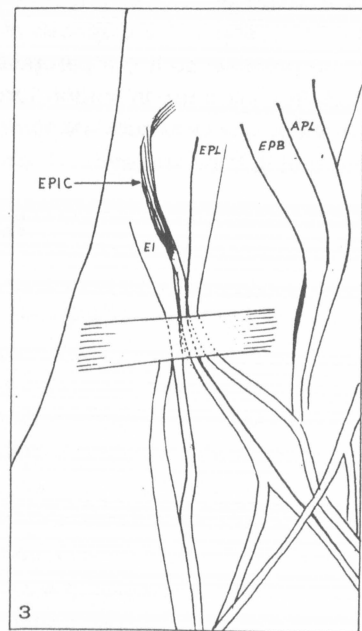
Arrows: Extensor pollicis and indicis communis (EPIC), and its doubled tendon.

APL: Abductor pollicis longus.

EPB: Extensor pollicis brevis.

EPL: Extensor pollicis longus.

EI: Extensor indicis proprius



Figür 3. Drawing of the extensor pollicis and indicis communis (EPIC) fused with the extensor indicis proprius.

APL: Abductor pollicis longus.

EPB: Extensor pollicis brevis.

EPL: Extensor pollicis longus.

EI: Extensor indicis proprius

are frequent variations (8). Chiu reported a case of a supernumerary extensor muscle originating from the bipennate extensor indicis proprius, and then fusing with the tendon of the extensor pollicis longus (9). Marwan described an additional extensor muscle to the thumb between the extensor indicis proprius and extensor pollicis longus with an undoubled tendon which he named extensor pollicis tertius (10).

Differing from the previous descriptions of the unipennate extensor pollicis and indicis communis the muscle we describe, was fused with the bipennate extensor indicis proprius and covered with a common fascia (1,2,5).

During development extensor muscles differentiate into 3 parts: a superficial layer that develops into the extensor digitorum communis, extensor carpi ulnaris, and extensor digiti minimi; a radial layer that divides into the brachioradialis and the extensor carpi radialis longus and brevis; and a deep layer that divides into 2 portions - a radial portion that becomes the extensor pollicis brevis and abductor pollicis longus and an ulnar portion that develops into the extensor pollicis longus and extensor indicis proprius (1,11-14). The deep layer is innervated by the deep branch of the radial nerve which also supplies our muscle. The fusion in our case indicates that muscle has the same developmental origin as the ulnar portion of the deep layer.

Variation of muscles of the forearm is not uncommon (2,4,6,8). The preoperative diagnosis of such variations is quite impossible; so it is a peroperative discovery. Although its clinical use in tendon surgery cannot be planned, the presence of such a variation should be kept in mind during hand surgery.

REFERENCES

1. Wood J. Variations in human myology observed during the winter session of 1867 - 1868 at King' s College, London. Proc R Soc London 16: 483-525, 1868.
2. Macalister . An Additional Observation on Muscular Anomalies in Human Anatomy. Trans. Irish Acad. 25: 1, 1871.
3. Caudwell EW, Anson BJ, Wright RR. The extensor indicis proprius muscle: A study of 263 consecutive specimens. Q. Bull. Northwest. Univ. Med. School 17: 267. 1943.
4. Kaplan EB. Functionel and Surgical Anatomy of the Hand. 2nd. Ed. Philadelphia: Lippincott, pp: 103-105, 1965.
5. Culver JE, Jr. Extensor pollicis and indicis communis tendon: A rare anatomic variation revisited. J. Hand Surg. 5A: 548, 1980.
6. Wagensell F. Untersuchungen über die Muskulatur der Chinesen. Z. Morphol. Antropol. 36:89, 1936.
7. Gruber W. Über den constanten Musculus extensor pollicis et indicis gewisser Saeugetiere homologen supernumeraeren Muskel beim Menschen. Virchows Arch. [A] 86: 471, 1881.
8. Bergman RA, Thompson SA, Afifi AK, Saadek FA. Compendium of Human Anatomic Variation. Baltimore: Urban and Schwarzenberg, pp: 40-41, 1988.
9. Chiu DT . Supernumerary extensor tendon to the thumb: A report on a rare anatomic variation. Plast. Reconstr. Surg. 68: 937, 1981.
10. Marwan F Abu-Hijleh . Extensor pollicis tertius: An Additional Extensor Muscle to the Thumb. Plast. Reconstr. Surg. 92: 340, 1992.
11. Boyes JH . Phylogeny and comparative anatomy. In: Bunnell' s surgery of the hand. 4th. ed. Philadelphia: JB Lippincott, pp:1-34, 1964 .
12. Cihak R . Ontogeny of the skeleton and intrinsic muscles of the human hand and foot. Ergep Anat. Entwicklungsgesch; 46: 190 - 194, 1972.
13. Yoshida Y. Anatomical study on the extensor digitorum profundus muscle in the Japanese. Okijamas Folia Anat Jpn 66: 339-354, 1990.
14. Williams PL, Bannister LH, Berry MM, Collins P, Dyson M, Dussek JE, Ferguson MWJ . Gray's Anatomy. 38th Ed. London: Churchill Livingstone, pp 851-852, 1995.