

I. U. Kütüphane ... Bşk.
Demirbaş No : M3487
Kayıt No :
Sınıflama No :

EFFECT OF HYPERBARIC OXYGEN THERAPY ON NERVE REGENERATION IN EARLY DIABETES

ATAKAN AYDIN, M.D.,^{1*} BURCU ÇELET ÖZDEN, M.D.,¹ SACIT KARAMÜRSEL, M.D.,² SEYHUN SOLAKOĞLU, M.D.,³ ŞAMİL AKTAŞ, M.D.,⁴ and METİN ERER, M.D.¹

Microsurgery - c. 24, s. 3 (2004)

Nerve regeneration in diabetes is essential for reversal of neuropathy as well as the recovery of nerves from injury due to acute nerve compression and entrapment. Endoneural hypoxia due to hyperglycemia-induced blood flow reductions is observed early in the course of diabetes, and the resultant ischemia plays a role in the diminished neural regeneration. Hyperbaric oxygen therapy is capable of producing tissue hyperoxia by raising oxygen tensions in ischemic tissues, and was shown to be beneficial in the reversal of experimental ischemic neuropathy. In this study, an experimental diabetes model was used to evaluate the functional and histomorphological effects of hyperbaric oxygen therapy on early diabetic nerve regeneration. Our results indicate that there is significant histomorphological impairment of nerve regeneration, even in very early stages of diabetes. However, no beneficial effects of hyperbaric oxygen therapy could be demonstrated at this stage. © 2004 Wiley-Liss, Inc.

Although recent therapeutic advances in the control of diabetes mellitus have contributed to measurable improvements in neuropathy, complete recovery is dependent on the regeneration of damaged axons and the reestablishment of fully functional connection with their targets. In addition to reversal of neuropathy, the regenerative process also plays a role in recovery of the peripheral nerve from injury due to acute nerve compression or entrapment injuries to which diabetic patients are highly susceptible,¹⁻⁴ and unfortunately less favorable results were reported on the recovery of diabetic patients following decompression surgery.⁵

Relative ischemia is a major factor which complicates peripheral nerve regeneration,⁶ and plays a role in the diminished regenerative capacity of diabetic nerves, along with other factors such as failed upregulation of neurotrophins⁷ and defective transport of cytoskeletal elements.⁸ Endoneural hypoxia due to hyperglycemia-induced blood flow reductions is observed early in the course of diabetes,⁹ and only modest increases in endoneural oxygenation are accomplished with normobaric oxygenation.¹⁰

Hyperbaric oxygen therapy is capable of producing tissue hyperoxia by raising oxygen tensions in ischemic tissues. Other potential beneficial effects are stimulation of angiogenesis, immune modification,¹¹ and microvas-

cular preservation.¹² Although the role of hyperbaric oxygen treatment on axon regeneration after peripheral nerve injury remains controversial, it was shown to rescue nerve fibers and partially reverse neuropathy in rats with experimentally induced ischemic neuropathy.¹³ Moreover, hyperbaric oxygen therapy was reported to have a positive effect in nerve energy metabolism, as suggested by biochemical changes and reversal of neuropathy in experimentally induced diabetes.¹⁴

In this study, an experimental diabetes model was used in order to evaluate the functional and histomorphological effects of hyperbaric oxygen therapy on early diabetic nerve regeneration.

MATERIALS AND METHODS

This study was approved by the Animal Care and Ethics Committee of our institution. Forty adult male Sprague-Dawley rats weighing 250–350 g (average weight, 293 g) were used. The animals were housed in cages at room temperature and were provided standard laboratory chow and water ad libitum. Four groups, each containing 10 animals, were randomly created. All surgical procedures were accomplished by the same surgeon (A.A.). With the aid of an operating microscope (Zeiss OPMI MD, Germany), the right sciatic nerve was exposed with a gluteal splitting incision, sectioned 1 cm before its trifurcation, and repaired with 10-0 nylon suture by the epineural technique. Groups 1 and 2 served as healthy controls. In groups 3 and 4, diabetes was induced by intraperitoneal injection of a single dose of streptozotocin (55 mg/kg) dissolved in citrate buffer 1 week prior to surgery. Establishment of diabetes was confirmed by measuring blood glucose levels with a glucometer.

Groups 2 and 4 underwent hyperbaric oxygen therapy with >95% O₂ at 2.5 atm, 60 min/day for 10 days

¹Division of Hand Surgery, Department of Plastic and Reconstructive Surgery, Istanbul Medical Faculty, Istanbul, Turkey

²Department of Physiology, Istanbul Medical Faculty, Istanbul, Turkey

³Department of Histology and Embryology, Istanbul Medical Faculty, Istanbul, Turkey

⁴Department of Underwater and Hyperbaric Medicine, Istanbul Medical Faculty, Istanbul, Turkey

*Correspondence to: Atakan Aydın, M.D., Orhantepe Mah., Kampyolu Sok., Palmiye Apt. No. 17, Daire: 5, Dragos, Kartal, 81540 Istanbul, Turkey. E-mail: atakanaydin@yahoo.com

Received 28 June 2003; Accepted 8 August 2003

Published online 15 April 2004 in Wiley InterScience (www.interscience.wiley.com). DOI: 10.1002/micr.20038

starting 24 h after neurotomy. Groups 1 and 3 were sham-treated. The sham treatment consisted of rats being transferred to a smaller cage about the same size as the pressure chamber at the same time points as the hyperbaric oxygen (HBO)-treated rats were put in the pressure chamber.

Functional evaluation was performed using walking-track analysis at 4, 8, and 12 weeks postoperatively. Electrophysiological measurements were taken at week 12, and animals were then sacrificed for histomorphometric studies along with light and electron microscopy analyses.

Functional Assessment

Motor function was assessed before the nerve transection and after the operation at 4-week intervals until week 12. The hind paws were dipped in water, and the rat was then allowed to walk on chemically treated paper (bromphenol blue) down a chute into a darkened shelter. Track measurements and sciatic function index (SFI) calculations were done by a technician who was blinded to the experimental group. The distance between the first and fifth toes (TS), the distance between the second and fourth toes (IT), and print length (PL) were taken, and SFI was calculated as described by Bain et al.¹⁵

Electrophysiological Evaluation

A Nihon Kohden RM 6000 polygraph was used as a bioelectric amplifier. The signal was filtered with a 30–1,000-Hz analogous band transparent filter. It was sampled at 2,048 Hz, and a numerical score was calculated. Nerve action potential was recorded by submaximal stimulation (average 2 v during 1.4 ms, using a BioScience 10550 Kymograph + Stimulator) at 1 Hz bipolarly. Three samples were taken for each group and averaged. The latency and amplitude of the first positive and negative waves were calculated and compared for each group at 12 weeks.^{16,17}

Histomorphometric Analysis

For evaluation of semithin sections, cross-sections each 1 mm wide were obtained from the sciatic nerve. Tissue specimens sized about 1 × 1 mm were fixed with 2.5% glutaraldehyde and 2% paraformaldehyde solution in 0.1 M sodium cacodylate buffer for 1 night, and then were postfixed with 0.1% osmium tetroxide solution in the same buffer. After a routine dehydration process in graded alcohol series and propylene oxide, specimens were embedded in Epon-812 embedding media. Semithin (1 μm) and thin (0.5 μm) cross-sections of the whole nerve were cut by ultra microtome (LKB). Images of

entire areas in each section were digitally recorded via camera (Pixel-View) attached to a research microscope (Olympus B-30). Analysis of digitized information, based on gray and white scales, was performed with Image Pro Plus 4.5.1 (Media Cybernetics) computer software. This system digitizes the images and displays them on a monitor with a calibration of 0.14 μm/pixel. Total and mean numbers and diameters of neuronal axons, as well as myelin sheath thickness, were calculated. Thin sections were stained with lead citrate and uranylacetate and evaluated via Jeol 100 electron microscope.

Statistical Analysis

Experimental data from four groups were compared using analysis of variance (ANOVA). When a statistically significant interaction was detected, groups were compared by Tukey test. All reported values are means, plus or minus the standard deviation. Statistical significance was presumed at $p < 0.05$.

RESULTS

All rats remained healthy throughout the study, without evidence of automutilation or foot ulceration (Table 1).

Table 1. SFI Values at 12 Weeks, Mean Axon Diameter, Myelin Sheath Thickness, and Axonal Count for Each Group

Walking-Track Analysis

At the beginning, SFI values were close to 0 for all animals, indicating normal function. After nerve transection and repair at week 4, SFI values of groups I, II, III, and IV were calculated as -70.9 ± 21.2 , -73.2 ± 12 , -72.8 ± 13.3 , and -70.2 ± 12.1 , respectively. At 8 weeks, SFI values increased to -44.7 ± 12 , -46 ± 9 , -59.6 ± 6.3 , and -50.1 ± 7.5 for groups I, II, III, and IV, respectively. The difference between groups was not statistically significant at either week 4 or week 8. The last evaluation was performed at the week 12, at which time neither group could reach preoperative normal values, but the best results were observed in group I (-24.8 ± 7.2), followed by group II (-26.8 ± 7.8), group III (-32.1 ± 9.4), and group IV (-43.1 ± 7.5). Differences between groups I vs. II and groups III vs. IV were not statistically significant (Fig. 1).

Electrophysiological Evaluation

The first positive wave latency values were: 7.8 ± 1.2 ms, 6.5 ± 0.9 ms, 6.4 ± 0.3 ms, and 7.2 ± 0.5 ms for groups I, II, III, and IV respectively. The first negative wave latency values were 19.7 ± 4.1 ms, 17.6

Table 1. SFI Values at 12 Weeks, Mean Axon Diameter, Myelin Sheath Thickness, and Axonal Count for Each Group

	Group 1	Group 2	Group 3	Group 4
SFI at 12 weeks	-24.8 ± 7.2	26.8 ± 7.8	43.1 ± 7.5	-32.1 ± 9.4
Diameter of myelinated fibers (μm)	7.9 ± 3.7	9.5 ± 2	5.8 ± 3.5	6.9 ± 3.4
Diameter of myelin sheath (μm)	1.42 ± 0.53	1.7 ± 0.3	1.1 ± 0.3	1.35 ± 0.49
Axonal count per area (number/61,700 μ ²)	368 ± 57	349 ± 62	156 ± 24	170 ± 21

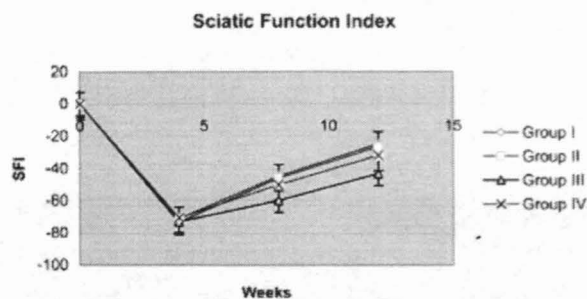


Figure 1. Sciatic function index evaluation at 4, 8, and 12 weeks.




Figure 3. Diameter of myelin sheet in groups 1-4.




Figure 2. Diameter of myelinated fibers in groups 1-4.

± 0.8 ms, 17.5 ± 0.7 ms, and 18.4 ± 0.3 ms for groups I, II, III, and IV, respectively. The first positive wave amplitude values were: 1.1 ± 0.3 mv, 1.1 ± 0.3 mv, 1.5 ± 0.06 mv, and 1.4 ± 0.06 mv for groups I, II, III and IV, respectively. The first negative wave amplitude values were -0.7 ± 0.3 mv, -1 ± 0.2 mv, -1 ± 0.03 mv, and -0.9 ± 0.05 mv for groups I, II, III, and IV, respectively. No statistically significant difference was observed between groups regarding latency and amplitude values of the nerve action potential.

Histomorphometric Analysis

Diameter of myelinated fibers. Mean values of myelinated fiber diameter in each group are summarized in Table 1 and Figure 2. Although better results were




Figure 4. Difference between numbers of axons in each group was not significant.

found in hyperbaric oxygen-treated groups in both diabetic and non diabetic animals (Fig. 5, 6), differences were not significant when compared with untreated groups (Fig. 7, 8). The only significant difference was found between group II and groups III/IV (ANOVA $F = 6.2, p < 0.05$).

Diameter of myelin sheath. Mean values of myelin sheath diameter in each group are summarized in Table 1 and Figure 3. Although better results were found in hyperbaric oxygen-treated groups in both diabetic and nondiabetic animals (Fig. 5, 6), the differences were not significant when compared with untreated groups (Fig. 7, 8). The only significant difference was found between group II and groups III/IV (ANOVA $F = 7.4, p < 0.05$).

Mean axonal count. The myelinated axons in the representative fields of each nerve were counted in

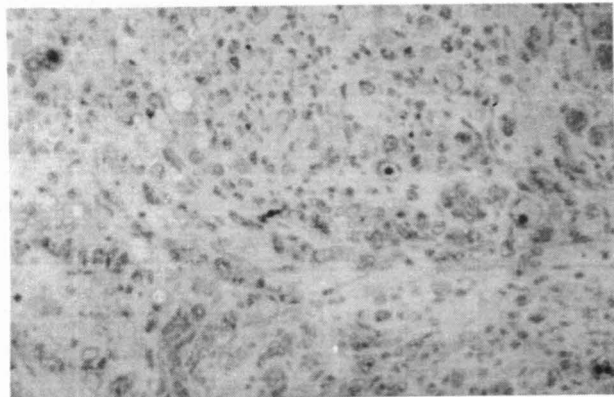


Figure 5. Light Microscopic view taken from the diabetic group treated with hyperbaric oxygen.

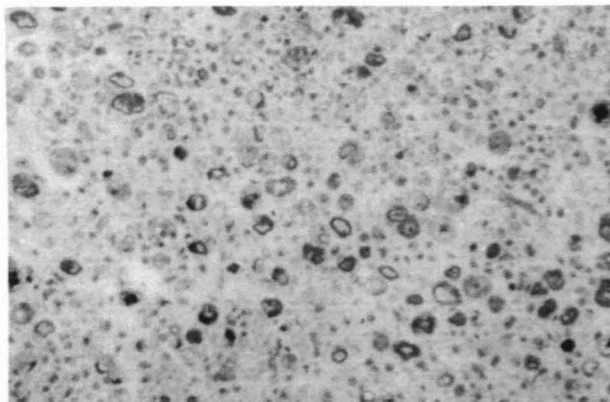


Figure 7. Light microscopic view taken from the untreated diabetic group.

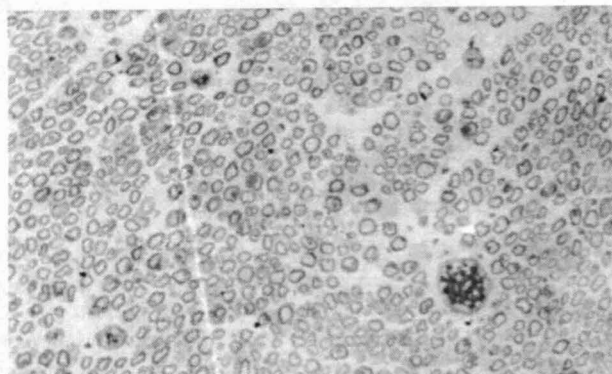


Figure 6. Light microscopic view taken from the healthy group treated with hyperbaric oxygen.

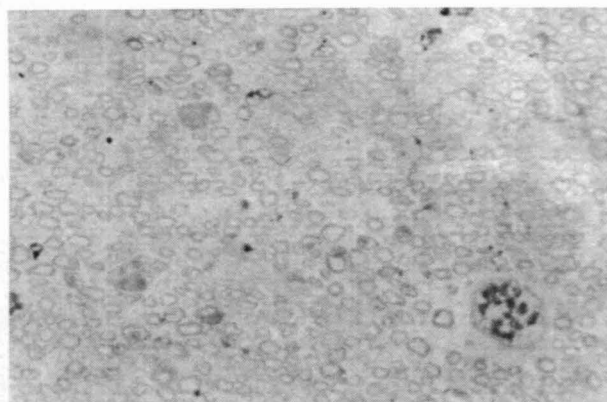


Figure 8. Light microscopic view taken from the untreated healthy group.

standard areas ($61,700 \mu^2$). Mean myelinated axonal counts of groups are summarized in Table I and Figure 4. No statistically significant difference was detected between groups.

Electron microscopy. Samples taken from the non-diabetic groups commonly showed organized nerve tissue with healthy, proliferating Schwann cells, suggesting ongoing regeneration (Fig. 9).

Mitochondria with regular cristae were observed (Fig. 10). In samples taken from the diabetic groups, nonmyelinated axons were more frequent, Schwann-cell degeneration with intranuclear vacuoles and mitochondria with irregular cristae were observed (Fig. 11). In accordance with the light microscopic finding of endoneurial fibrosis, collagen bundles were observed on electron microscopy (Fig. 12).

DISCUSSION

Underlying factors in diabetic neuropathy have been extensively studied, and biochemical abnormalities in

experimental models such as reduced nerve myoinositol concentration,¹⁸ decreased rate of synthesis and transport of intra-axonal proteins,^{19,20} reduced incorporation of glycolipids and amino acids into myelin²¹ and excessive intracellular accumulation of glycogen⁽²²⁻²⁵⁾ suggest a metabolic cause. Since energy production in neural tissue in vitro is mainly dependent on oxidative metabolism, these metabolic changes could be attributed to endoneurial ischemia and resultant hypoxia.

Although neuropathy is an established component of chronic diabetes, impairment of nerve regeneration in these individuals is controversial. Despite the presence of clinical and experimental data that suggest good regenerative capacity in the diabetic nerves^{26,27} there also exist studies that contradict these findings.²⁸⁻³² Impaired regenerative success in diabetes is reported to be a result of defects in several stages of the regenerative process such as onset of regeneration,²⁹ rate of elongation of axonal sprouts,³³ and maturation of nerve fibers.^{34,35} These pathologies in the regenerative process

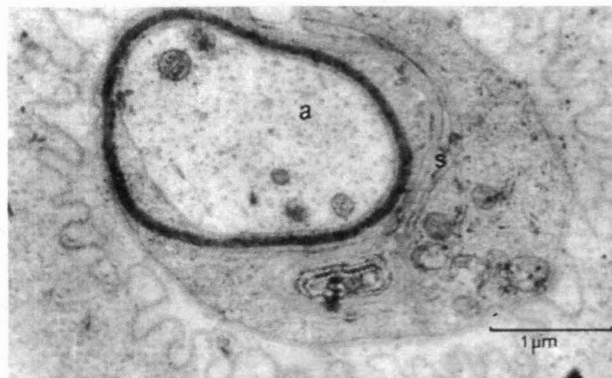


Figure 9. Electron microscopic view taken from healthy group treated with hyperbaric oxygen. **a**, axon; **s**, Schwann cell.

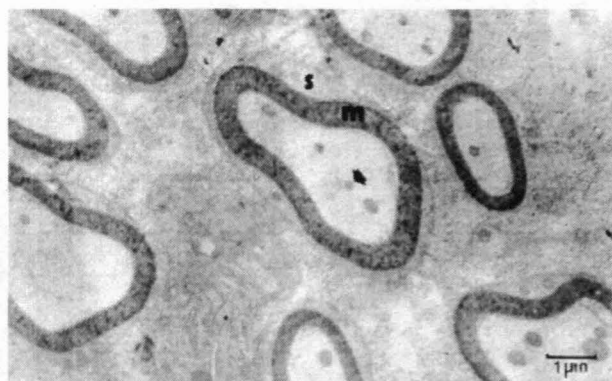

Figure 10. Electron microscopic view taken from healthy group which did not undergo hyperbaric oxygen therapy. **m**, myelin; **s**, Schwann cell.

could be attributed to the microangiopathy of the vasovasorum in the form of diminished hyperemic response to injury, which renders an unfavorable local environment for nerve regeneration.³⁶ Moreover, hyperglycemia-induced blood flow reductions, already observed early in diabetes,⁹ may create a relatively ischemic regenerative microenvironment, even before the microangiopathic changes of chronic diabetes are established.

Hyperbaric oxygen therapy (HBO) is commonly used in the treatment of ischemic injuries such as acute trauma, refractory wounds, tissue flap, and grafts with compromised circulation and osteoradionecrosis.³⁷ Since nerve injuries also suffer from the ischemic changes similar to the pathophysiologic processes observed in ischemic-reperfusion injuries of the muscle and skin, a possible beneficial effect of HBO on nerve regeneration has been questioned, with varying results. Enhanced axon regeneration and my-

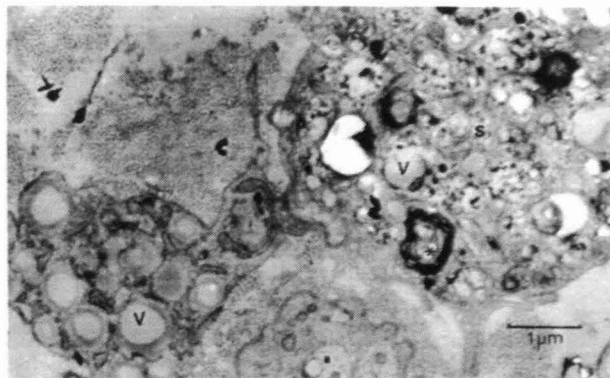


Figure 11. Electron microscopic view taken from diabetic group which did not undergo hyperbaric oxygen therapy, **a**, axon without myelin sheet; **s**, degenerating Schwann cell; **v**, intranuclear vacuoles; **c**, collagen; *multilamellar inclusions.

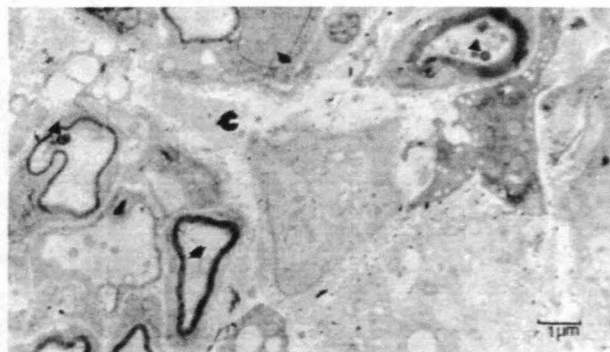

Figure 12. Electron microscopic view taken from diabetic group treated with hyperbaric oxygen, **c**, collagen; **arrow**, irregular mitochondria; **arrowhead**, intranuclear vacuoles.

elination of regenerated axons were reported after crush injury of the sciatic nerve in rats and rabbits.³⁸⁻⁴⁰ In addition, HBO was shown to improve functional recovery following nerve transection and epineural repair in the rat sciatic nerve.¹² On the other hand, it was reported that neither axon regeneration nor functional recovery was improved by HBO following transection and entubulation repair of the rat peroneal nerve.⁴¹

The beneficial effect of HBO has also been studied in experimentally induced nerve ischemia models^{13,14,42} and it was suggested that in order for the HBO to have a positive effect on nerve regeneration, some blood flow through the ischemic nerve should be preserved rather than a complete destruction of the circulation.⁴² This is in accordance with the reduction in blood flow detected in both early and chronic experimental diabetes^{9,43} and could help to interpret the biochemical changes that suggest enhanced nerve energy metabolism induced by

HBO in chronic streptozotocin (STZ) diabetic peripheral nerves.

The purpose of this study was both to evaluate the effect of diabetes on nerve regeneration in the early stages of the disease, and to investigate whether hyperbaric oxygen therapy could improve any possible impairment during this process.

In accordance with studies which reported impaired nerve regeneration in diabetes,²⁸⁻³² the statistically significant decrease in diameter of myelinated fibers and myelin sheath of diabetic animals, as observed in our study, further implies that this impairment begins in the very early stages of the disease. Studies showed that the natural response to ischemia after nerve injury is an increase in endoneurial blood flow to address the increased nutrient and oxygen consumption of regenerating axons and cellular elements during repair.^{36,44} It was also reported that this hyperemic response after injury is altered in diabetic animals.³⁶ A reduction in nerve blood flow related to conduction deficits was also shown to occur as early as 1 week after diabetes induction,⁹ and although regenerative success is noted to be inversely related to the duration of diabetes in rats,⁴⁵ such a creation of a short-term microenvironment with relative ischemia, along with delayed mitogenicity of support and migratory cells, can account for a slowed regeneration rate at an early stage.

In our study, we did not find any functional or histomorphological improvement in nerve regeneration at the early stages of diabetes with hyperbaric oxygen therapy. The potential benefits of hyperbaric oxygen therapy have been overshadowed by evidence that it generates reduced oxygen species⁴⁶ and the presence of oxidative stress in peripheral nerves, along with blood-nerve barrier impairment is well-documented.⁴⁷⁻⁵⁰ According to the results of our study, it is possible that nerve regeneration in early diabetes was somehow more susceptible to oxidative stress induced by hyperbaric oxygen therapy when compared with the established neuropathy in chronic stages of this disease. Objective evaluation of the possible presence of oxidative stress by further measurements could help to explain our findings. Although salvage of ischemic peripheral nerves with hyperbaric oxygen therapy was possible, the beneficial effects of this intervention were found to be closely related to alterations in local blood flow.⁴³ Insignificant results, as found in our study, could be better explained if alterations in endoneurial blood flow could be monitored during hyperbaric oxygen therapy.

In conclusion, our results indicate that there is significant histomorphological impairment in nerve regeneration, even in the very early stages of diabetes. However, no beneficial effects of hyperbaric oxygen therapy could be demonstrated at this stage.

REFERENCES

- Shahani B, Spalding JM. Diabetes mellitus presenting with bilateral foot-drop. *Lancet* 1969;1:930-931.
- Phalen GS. Reflections on 21 years' experience with the carpal tunnel syndrome. *JAMA* 1970; 25:1365-1367.
- Fraser DM, Campbell IW, Ewing DJ, Clarke BF. Mononeuropathy in diabetes mellitus. *Diabetes* 1979;28:96-101.
- Stevens JC, Beard CM, O'Fallon WM, Kurland LT. Conditions associated with carpal tunnel syndrome. *Mayo Clin Proc* 1992; 67:541-548.
- Haupt WF, Wintzer G, Schop A, Lottgen J, Pawlik G. Long term results of carpal tunnel decompression. Assessment of 60 cases. *J Hand Surg [Br]* 1993;18:471-474.
- Korthals JK, Korthals MA, Wisniewski HM. Progression of regeneration after nerve infarction. *Brain Res* 1991;552:41-46.
- Unger JW, Klitzsch T, Pera S, Reiter R. Nerve growth factor (NGF) and diabetic neuropathy in the rat: morphological investigations of the sural nerve, dorsal root ganglion and spinal cord. *Exp Neurol* 1998; 153:23-34.
- Mc Quarrie IG, Lasek RJ. Transport of cytoskeletal elements from parent axons into regenerating daughter axons. *J Neurosci* 1989; 9:436-446.
- Cameron NE, Cotter MA, Low PA. Nerve blood flow in early experimental diabetes in rats: relation to conduction deficits. *Am J Physiol* 1991;261:1-8.
- Tuck RR, Schmelzer JD, Low PA. Endoneurial blood flow and oxygen tension in the sciatic nerves of rats with experimental diabetic neuropathy. *Brain* 1984;107:935-950.
- Gadd MA, McClellan DS, Neuman TS, Hansbrough JF. Effect of hyperbaric oxygen on murine neutrophil and T-lymphocyte functions. *Crit Care Med* 1990;18:974-979.
- Zamboni WA, Brown RE, Roth AC, Mathur A, Stephenson LL. Functional evaluation of peripheral-nerve repair and the effect of hyperbaric oxygen. *J Reconstr Microsurg* 1995; 11:27-30.
- Kihara M, McManis PG, Schmelzer JD, Kihara Y, Low PA. Experimental ischemic neuropathy: salvage with hyperbaric oxygenation. *Ann Neurol* 1995;37:89-94.
- Low PA, Schmelzer JD, Ward KK, Curran GL, Poduslo JF. Effect of hyperbaric oxygenation on normal and chronic streptozotocin diabetic peripheral nerves. *Exp Neurol* 1988;99:201-212.
- Bain JR, Mckinnon SE, Hunter DA. Functional evaluation of complete sciatic, peroneal and posterior tibial nerve lesions in the rat. *Plast Reconstr Surg* 1989;83:129.
- Ganong WF. *Review of medical physiology*. Connecticut: Appleton and Lange;1989.
- Kandel ER, Schwartz JH, Jessel TM. *Principles of Neural Science*. McGraw Hill, New York; 2000.
- Greene DA, De Jesus PV Jr, Winegrad AI. Effects of insulin and dietary myoinositol on impaired peripheral motor nerve conduction velocity in acute streptozotocin diabetes. *J Clin Invest* 1975;55:1326-1336.
- Sidenius P, Jakobsen J. Retrograde axonal transport. A possible role in the development of neuropathy. *Diabetologia* 1981;20:110-112.
- Sidenius P, Jakobsen J. Reversibility and preventability of the decrease in slow axonal transport velocity in experimental diabetes. *Diabetes* 1982;31:689-693.
- Spritz N, Singh H, Marinaro B. Metabolism of peripheral nerve myelin in experimental diabetes. *J Clin Invest* 1975;55:1049-1056.
- Powell H, Knox D, Lee S, Charters AC, Orloff M, Garrett R, Lampert P. Alloxan diabetic neuropathy: electron microscopic studies. *Neurology*; 1977;27:60-66.
- Bestetti G, Zemp C, Probst D, Rossi GL. Neuropathy and myopathy in the diaphragm of rats after 12 months of streptozotocin-induced diabetes mellitus. A light-, electron-microscopic, and morphometric study. *Acta Neuropathol (Berl)* 1981;55:11-20.
- Moore SA, Peterson RG, Felten DL, O'Connor BL. Glycogen accumulation in tibial nerves of experimentally diabetic and aging control rats. *J Neurol Sci* 1981;52:289-303.

25. Sima AA. Peripheral neuropathy in the spontaneously diabetic BB-Wistar-rat. An ultrastructural study. *Acta Neuropathol (Berl)* 1980;51:223-227.
26. Babovic S, Rens AM, Dellon AL, Angel MF, Im MJ, Manson PN. Nerve regeneration in diabetic rats. *Microsurgery* 1998;18:9-11.
27. Dellon AL, Dellon ES, Seiler WA. IV. Effect of tarsal tunnel decompression in the streptozotocin-induced diabetic rat. *Microsurgery* 1994;15:265-268.
28. Eliasson SG. Regeneration process in experimental diabetic neuropathies. *Trans Am Neurol Assoc* 1965;90:35-37.
29. Bisby MA. Axonal transport of labelled protein and regeneration rate in nerves of streptozotocin diabetic rats. *Exp Neurol* 1980;69:74-84.
30. Sharma AK, Thomas PK. Peripheral nerve regeneration in experimental diabetes. *J Neurol Sci* 1975;24:417-424.
31. Longo FM, Powell HC, Lebeau J, Gerrero MR, Heckman H, Myers RR. Delayed nerve regeneration in streptozotocin diabetic rats. *Muscle Nerve* 1986;9:385-393.
32. Sharma AK, Bajada S, Thomas PK. Influence of streptozotocin-induced diabetes on myelinated nerve fibre maturation and on body growth in the rat. *Acta Neuropathol (Berl)* 1981;53:257-265.
33. Ekstrom AR, Kanje M, Skottner A. Nerve regeneration and serum levels of insulin-like growth factor-1 in rats with streptozotocin induced insulin deficiency. *Brain Res* 1989;496:141-147.
34. Tantuwaya VS, Bailey SB, Schmidt RE, Villadiego A, Tong JX, Rich KM. Peripheral nerve regeneration through silicone chambers in streptozotocin induced diabetic rats. *Brain Res* 1997;758:58-66.
35. Kennedy JM, Zochodne DW. The regenerative deficit of peripheral nerves in experimental diabetes: its extent, timing and possible mechanism. *Brain* 2000; 123:2118-2129.
36. Kennedy JM, Zochodne DW. Influence of experimental diabetes on the microcirculation of injured peripheral nerve: functional and morphological aspects. *Diabetes* 2002;51:2233-2240.
37. Kindwall EP, (editor). *Hyperbaric medicine practice*. Flagstaff, AZ: Best Publishing Co.;1995.
38. Haapaniemi T, Nylander G, Kanje M, Dahlin L. Hyperbaric oxygen treatment enhances regeneration of the rat sciatic nerve. *Exp Neurol* 1998;149:433-438.
39. Liu QL, He BP. Effects of hyperbaric oxygen therapy on rat sciatic nerve injury. *Undersea Hyperb Med*, 1994;21:341-343.
40. Bradshaw PO, Nelson AG, Fanton JW, Yates T, Kagan-Hallet KS. Effect of hyperbaric oxygenation on peripheral nerve regeneration in adult male rabbits. *Undersea Hyperb Med* 1996; 23:107-113.
41. Santos PM, Zamboni WA, Williams SL, Covey JF, Kienstra MA. Hyperbaric oxygen treatment after rat peroneal nerve transection and entubulation. *Otolaryngol Head Neck Surg* 1996;114: 424-434.
42. Bajrovic FF, Sketelj J, Jug M, Gril I, Mekjavic IB. The effect of hyperbaric oxygen treatment on early regeneration of sensory axons after nerve crush in the rat. *J Peripher Nerv Syst* 2002; 7:141-148.
43. Kihara M, McManis PG, Schmelzer JD, Kihara Y, Low PA. Experimental ischemic neuropathy: salvage with hyperbaric oxygenation. *Ann Neurol* 1995;37:89-94.
44. Holzer P. Local effector functions of capsaicin-sensitive sensory nerve endings: involvement of tachykinins, calcitonin gene-related peptide and other neuropeptides. *Neuroscience* 1988;24:739-768.
45. Ekstrom PA, Tomlison DR. Impaired nerve regeneration in streptozotocin diabetic rats is improved by treatment with gangliosides. *Exp Neurol* 1990;109:200-203.
46. Fridovich I. Hypoxia and oxygen toxicity. *Adv Neurol* 1979;26: 255-259.
47. Low PA, Lagerlund TD, McManis PG. Nerve blood flow and oxygen delivery in normal, diabetic and ischemic neuropathy. *Int Rev Neurobiol* 1989;31:355-438.
48. Low PA, Nickander KK. Oxygen free radical effects in sciatic nerve in experimental diabetes. *Diabetes* 1991;40:873-877.
49. Ward KK, Low PA, Schmelzer JD, Zochodne DW. Prostacyclin and noradrenaline in peripheral nerve of chronic experimental diabetes in rats. *Brain* 1989;112:197-208.
50. Schmelzer JD, Zochodne DW, Low PA. Ischemic and reperfusion injury of rat peripheral nerve. *Proc Natl Acad Sci USA* 1989; 86:1639-1642.